

## LINCOLN MEMORABILIA IN THE MEDICAL MUSEUM OF THE ARMED FORCES INSTITUTE OF PATHOLOGY

HELEN R. PURTLE

Although Lincoln memorabilia are displayed in museums in various parts of the country, the relics associated with the assassination of Abraham Lincoln are logically and appropriately housed in the Medical Museum. Since the founding of the Army Medical Museum in 1862, one of its aims has been to collect material of medico-historical importance. And where better to begin than with memorabilia of the man who held the high offices of President of the United States and Commander-in-Chief of the Army during the founding years of the Museum?

Abraham Lincoln, shot on April 14, 1865, was attended in his last hours by Army doctors and by his personal physician, Dr. Robert King Stone; he died on April 15. Among those present were Surgeon General Joseph K. Barnes, Dr. Charles S. Taft, Dr. C. H. Lieberman and Dr. Charles A. Leale, a young Army surgeon, who was in the theater when Lincoln was shot and was the first to reach his side.

Not until some thirty-five years after Lincoln's death, however, were any of the relics relating to the assassination contributed to the Army Medical Museum. The acquisitions now housed here, and on permanent display, comprise the Seward-Barnes Chinese plate, copies of Lincoln's mask and casts of his hands, and clippings of Lincoln's hair from the wound area. In addition, there are either original illustrations or prints of the scenes around the death bed, the bloodstained cuffs of one of the physicians who participated in the autopsy, a copy of Dr. Leale's *Lincoln's Last Hours*, the fatal bullet, fragments of bone, and the probe used in the autopsy. A section of the spinal cord and fragments of vertebrae from the assassin, John Wilkes Booth, are also in the collection.

*Seward-Barnes Chinese Plate.* At the time that Lincoln was shot, there was a cleverly conceived but clumsily executed plot directed by John Wilkes Booth to murder not only the President but his entire cabinet. George A. Atzerodt was assigned to kill Vice-President Johnson, but lost his courage. When it was learned that General Ulysses S. Grant was to sit in the Presidential box, Lewis Paine, a stalwart young deserter from the Confederate Army, was selected to kill Grant. However, at the last moment he changed his plans and left Washington. Paine was then

assigned to kill William Henry Seward, the Secretary of State. The slaying was scheduled for the same time that Booth was to take Lincoln's life. The attempt on Seward's life was thwarted by a metal brace which he was wearing because of a fractured jaw.

Surgeon General Joseph K. Barnes was called on the night of the 14th of April to treat Mr. Seward. In his testimony for the prosecution on May 19, 1865, Barnes (1) reported that the Secretary was severely wounded "by a gash in the right cheek, which passed around to the angle of the jaw, by a stab in the right neck, and by a stab in the left side of the neck." In appreciation of his services, Seward presented to General Barnes a set of Chinese plates which were made in Canton (or near Canton). One of these plates donated in 1900 to the Army Medical Museum by General Barnes' widow, bears a design of Chinese characters in gold lettering which translated read: "Thanks from Prime Minister Seward to the great American Physician Dr. Barnes." One scene depicts two people at a game, the other is a family scene. In accepting this gift March 14, 1900, General George M. Sternberg wrote to Mrs. Barnes: ". . . This will be of interest as a relic associated with the tragic death of President Lincoln, and will be deposited in the Army Medical Museum as a gift from you and a souvenir of the event referred to, and of the relations of your honored husband to President Lincoln and his distinguished Secretary of State."

*The Lincoln Life-Mask and Hands.* In February 1942, Avel Fairbanks, sculptor, offered to make for the Army Medical Museum copies of Lincoln's life mask and hands. These reproductions by Mr. Fairbanks were made from castings loaned to him by Mr. Thomas Starr, President of the Lincoln Club of Detroit. Mr. Starr had made them from the original molds cast by Leonard Volk (2) in 1860, the mask in preparation for a bust and the hands to be used as models for a statue of Lincoln. Fairbanks stated in a personal communication to Colonel J. E. Ash:

I have seen many reproductions of the Volk mask and hands but in none, before these loaned to me by Mr. Starr, have I seen such details as his had. The wrinkles and even the texture of the quality of Lincoln's face were particularly noticeable. Also the skin folds on the back of the left hand show very prominently. One might question why the skin folds are not as noticeable on the back of the right hand but they would be if in the same position as the left. I have tried holding a stick and bending my wrist in the position of that of Lincoln's hand and I find that the skin becomes stretched. This accounts for the difference which you may notice.

The casts of Lincoln's face and hands made by Volk are in the National Museum in Washington (3). The copies made by Fairbanks are in the Medical Museum, Armed Forces Institute of Pathology.

*Lincoln's Hair.* A small amount of hair from the area surrounding President Lincoln's wound was removed by Dr. C. H. Liebermann, one of the surgeons in attendance at the bedside, and given by him to Surgeon General Joseph K. Barnes. Dr. Stone, who presided at the autopsy, presented a lock of hair to Mrs. Lincoln, at her request, and to each of the surgeons present at the autopsy. Hair from the wound area was later contributed to the Museum; one lock by Mrs. Barnes, another by Mrs. George M. Sternberg.

*Sketch of the Death-Bed Scene of Abraham Lincoln* (Fig. 1). In 1933 Dr. Samuel B. Sturgis contributed the original sketch of the death-bed scene drawn by Hermann Faber, a medical artist on duty at the Army Medical Museum, accompanied by an affidavit by Erwin Faber:

This sketch of the death-bed of Abraham Lincoln, was made by my father, Mr. Hermann Faber, then Hospital Steward, attached to the Surgeon General's Department, Washington, D. C., directly under Generals Barnes and Woodward, (Ed. note—Woodward was an Assistant Surgeon, U. S. A., not a general.), as artist to illustrate the Medical War Record. Immediately after the removal of President Lincoln's body, Mr. Faber entered the house and room in which he died. Nothing had been disturbed, the bed, chairs, etc., were still in place. This sketch was immediately shown to Dr. Woodward who gave all the detail of the positions of those present at the time of the demise of Lincoln. Doctors Woodward and Barnes both approved of this drawing as to its correctness and accuracy. It is without doubt the first and only sketch made at that time. He (Faber) also removed the blood-stained pillow case, a piece of which is in the collection at the College of Physicians in Philadelphia.

In spite of Mr. Faber's positive statement about his father's sketch of the death-bed scene, other drawings were made about the same time, among them one by Albert Berghaus, which appeared in Frank Leslie's *Illustrated Weekly*, April 29, 1865, another by Litchfield, which appeared in *Harper's Weekly*, May 6, 1865, and still another by Major A. N. Rockwell. Copies of these have been obtained recently for the archives of the Medical Museum.

*Lincoln's Last Hours.* In November 1951 Mrs. James Harper deposited in the Medical Museum, in addition to other family memorabilia, a booklet *Lincoln's Last Hours* written by her grandfather, Dr. Charles A. Leale, the first physician to reach President Lincoln after the fatal shooting. It was Dr. Leale's diagnosis and prognosis, "His wound is mortal; it is impossible for him to recover," that was telegraphed over the world, and his treatment, according to his account, that prolonged the life of the President until shortly after seven o'clock the next morning; Dr. Leale remained with the President until he died.



FIG. 1. Sketch of death-bed scene, by Hermann Faber. Persons around Lincoln who can be identified: 1. Gideon Welles, Sec. of Navy, 2. Salmon P. Chase, Sec. of Treasury, 3. Dr. Robert King Stone, Lincoln's personal physician, 4. Chas. Sumner, U. S. Senator, 5. Dr. Chas. H. Crane, Asst. Surg. Gen., 6. Dr. Jos. K. Barnes, Surg. Gen., 7. Henry W. Halleck, Maj. Gen., 8. Edwin McMasters Stanton, Sec. of War.

*Bloodstained Cuffs.* Mr. Bridgham Curtis sent a letter to the Office of the Surgeon General on August 6, 1947, asking if the Army Medical Museum would care to accept two relics of the autopsy performed on Lincoln by his father, Dr. Edward Curtis, and Dr. J. J. Woodward, Assistant Surgeons, U. S. A., the latter assigned to duty at the Army Medical Museum. These relics, the bloodstained cuffs of the undershirt Dr. Curtis was wearing at the time of the autopsy, and a splinter of skull bone from the fatal wound area were received in the Museum on September 12, 1947, accompanied by a sworn affidavit dated May 11, 1926, signed by Dr. Curtis' widow, Mrs Augusta L. Curtis.

The affidavit itself contains some facts of pertinent historical interest:

Augusta L. Curtis, being duly sworn, deposes and says: I am the widow of the late Edward Curtis, M. D. who died in New York City on November 28, 1912;

I was married to Dr. Curtis on November 16, 1864;

During the Civil War, Dr. Edward Curtis was an Assistant-Surgeon in the Medical Corps of the U. S. Army and at the time of Lincoln's assassination was stationed in Washington and was on duty in the office of the Surgeon General.

After Lincoln's death and on April 15, 1865, Dr. Curtis and Dr. J. Janvier Woodward, who was also in the Medical Corps of the Army, at the direction of the Surgeon General of the U. S. Army, performed an autopsy on the body of the President.

A brief account of the autopsy with a note of the results was published in the New York Times for Monday, April 17, 1865. Dr. Curtis also wrote an account of the autopsy which was published in the New York Sun for Sunday, April 12, 1903.

At the time the autopsy was performed we were living at a boarding house in Washington situated on the first block of Vermont Avenue just off from Lafayette Square to the North. When Dr. Curtis returned from the autopsy and was changing his clothes he found that a few drops of the President's blood had stained the cuffs of his shirt and showed them to me. I thereupon cut the cuffs from the shirt and put them away in an envelope which has been in my possession ever since. On this envelope Dr. Curtis endorsed in his handwriting the following:

Shirt sleeves soiled with the blood of  
President Abraham Lincoln at the autopsy  
on his body April 15, 1865.

Edward Curtis, Asst. Surg. U. S. A.

At the same time, to-wit, April 15, 1865, while Dr. Curtis in my presence was cleaning his surgical instruments which he had used to perform the autopsy he found on one of them and showed to me a tiny splinter of bone from President Lincoln's head, which, he said, had evidently been driven into the brain by the bullet, and which had adhered to the surgical instrument. Dr. Curtis wrapped this splinter of bone in my presence in a small piece of writing paper and endorsed thereon in his handwriting the following:

## Splinter of bone from skull of Abraham Lincoln

. . . I have this day, May 11, 1926, again shown the said splinter of bone and the said letter of May 17, 1865, and the said cuffs and said endorsed envelope to my son Bridgham Curtis, and have directed him to place and keep the same with this affidavit for the purpose of verification and identification.

*The Bullet that Killed Lincoln.* Dr. Stone (4) was given permission to conduct the postmortem examination, and of this he has written: ". . . previous to the process of embalment, I proceeded to the autopsy of our late President, having requested my friends Assistant Surgeons J. Janvier Woodward and Curtis, U. S. A. to be present and as skillful and tried anatomists to conduct the examination. There were present Surgeon General Barnes, U. S. A., Dr. Crane, U. S. A., and Dr. Taft, U. S. A.," and a number of other physicians (5).

Benn Pitman, Recorder for the Commission, a military body appointed to conduct the trial of the conspirators, states that Dr. Robert King Stone gave the following testimony for the prosecution (6):

. . . an examination (postmortem) was made in the presence of Surgeon General Barnes, Dr. Curtis and Dr. Woodward of the Army. We traced the wound through the brain, and the ball was found in the anterior part of the same side of the brain, the left side (7); it was a large ball, resembling those which are shot from the pistol known as the Derringer; an unusually large ball—that is, larger than those used in the ordinary pocket revolvers. It was a leaden hand-made ball, and was flattened somewhat in its passage through the skull, and a portion had been cut off in going through the bone. I marked the ball "A. L.," the initials of the late President, and in the presence of the Secretary of War, in his office, enclosed it in an envelope, sealed it with my private seal, and indorsed it with my name. The Secretary enclosed it in another envelope, which he endorsed in like manner, and sealed with his private seal. It was left in his custody, and he ordered it to be placed among the archives of his department.

(An official envelope, sealed with the official seal of the Secretary of War, was here opened by the Judge Advocate in the presence of the witness, from which was taken a Derringer pistol and an envelope containing a leaden ball in *two* pieces.)

This is the ball which I extracted from the head of the President; I recognize it from the mark which I put upon it with my pen-knife, as well as from the shape of the ball. This smaller piece is the fragment which was cut off in its passage through the skull. The ball was flattened, as I have before described.

The bullet, together with several fragments of bone removed from Lincoln's skull, and the probe used to remove the bullet were transferred to the Medical Museum by the Lincoln Museum of the National Capital Park Service on June 20, 1956. These objects had been in the Judge Advocate's Office, War Department, until February 5, 1940, when they were transferred to the Lincoln Museum. As the bullet had never

been on display prior to its receipt in the Medical Museum, it is quite possible that many believe it was buried with Lincoln.

The bullet is 43.75 mm. and is described as exceedingly hard lead, made of britannia metal—a mixture of antimony, tin and copper and soft lead. Although the discovery of the bullet has been described by others, Dr. Edward Curtis' (8) statement is perhaps most dramatic:

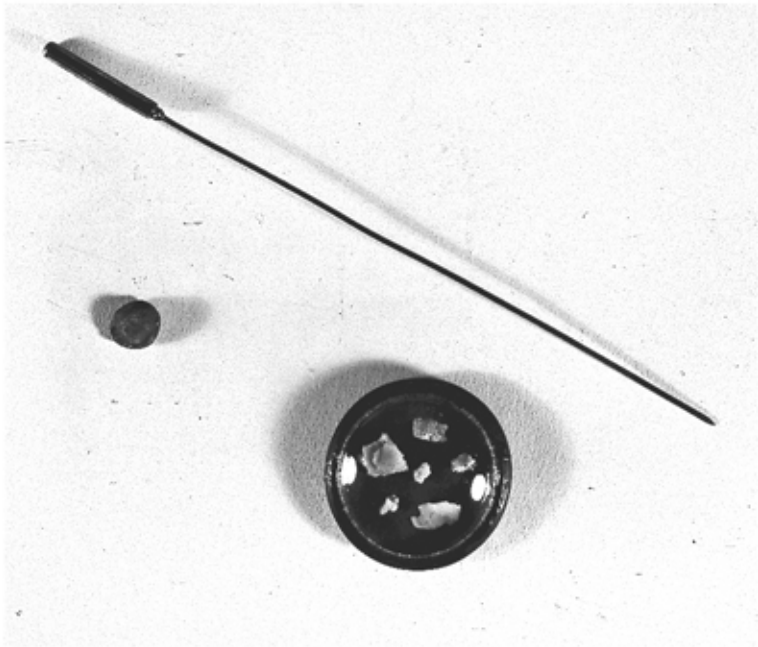
... an examination is instituted and there is laid bare what a few short hours since was the fountainhead of a wit and a wisdom that could save a nation. The part is lifted from its seat, when suddenly, from out a cruel vent that traverses it from end to end, through these very fingers there slips a something hard—slips and falls with a metal's mocking clatter into a basin set beneath. The search is satisfied; a little pellet of lead.

On 29 April 1865, Surgeon General Joseph K. Barnes deposited in the Medical Museum a portion of the spinal cord and a section of the 3rd, 4th and 5th cervical vertebrae which were removed at autopsy from the body of the assassin, John Wilkes Booth (9). The spinal cord was perforated from right to left and the laminae of the 4th and 5th vertebrae were fractured by a conoidal pistol ball, fired at a distance of a few yards. Booth died two hours after the injury.

These relics pertaining to the assassination of President Abraham Lincoln have been incorporated in an exhibit which is on permanent display in the Medical Museum.

#### REFERENCES

1. Pitman, Benn: *The Assassination of Abraham Lincoln and The Trial of the Conspirators*, p. 157, New York, 1865.
2. Volk, Leonard W.: The Lincoln Life Mask and How it was Made. *Century Magazine*, December 1881.
3. Stewart, T. D.: An Anthropologist Looks at Lincoln. *Ann. Report of Smithsonian Institution*, 1952.
4. Stone, Robert King: Account of the Post Mortem Performed upon President Lincoln. Manuscript dated April 15, 1865, in possession of Dr. Max Thorek, Chicago, Ill.
5. Taft, Dr. C. S.: The Last Hours of Abraham Lincoln. *Med. & Surg. Reporter*, 12: 452-454, 1865.
6. Pitman, Benn: *The Assassination of Abraham Lincoln and the Trial of the Conspirators*, p. 81-82, New York, 1865.
7. Gilmore, Hugh R. Jr., Col. MC, USA: Medical Aspects of the Assassination of Abraham Lincoln. *Proc. Roy. Soc. of Med.* 47: 103-108, 1954.
8. Curtis, Edward A.: Last Professional Service of the War. *Glimpses of Hospital Life in War Times*, 4: 63-65, 1865.
9. Herring, A. L. Jr., M. D. and Robert W. Prichard, M. D.: The Curse of Cain. *Surg. Gyn. & Obst.*, 93: 645, 653, 1951.



Bullet that killed Abraham Lincoln, along with bullet probe and Lincoln's skull fragments.